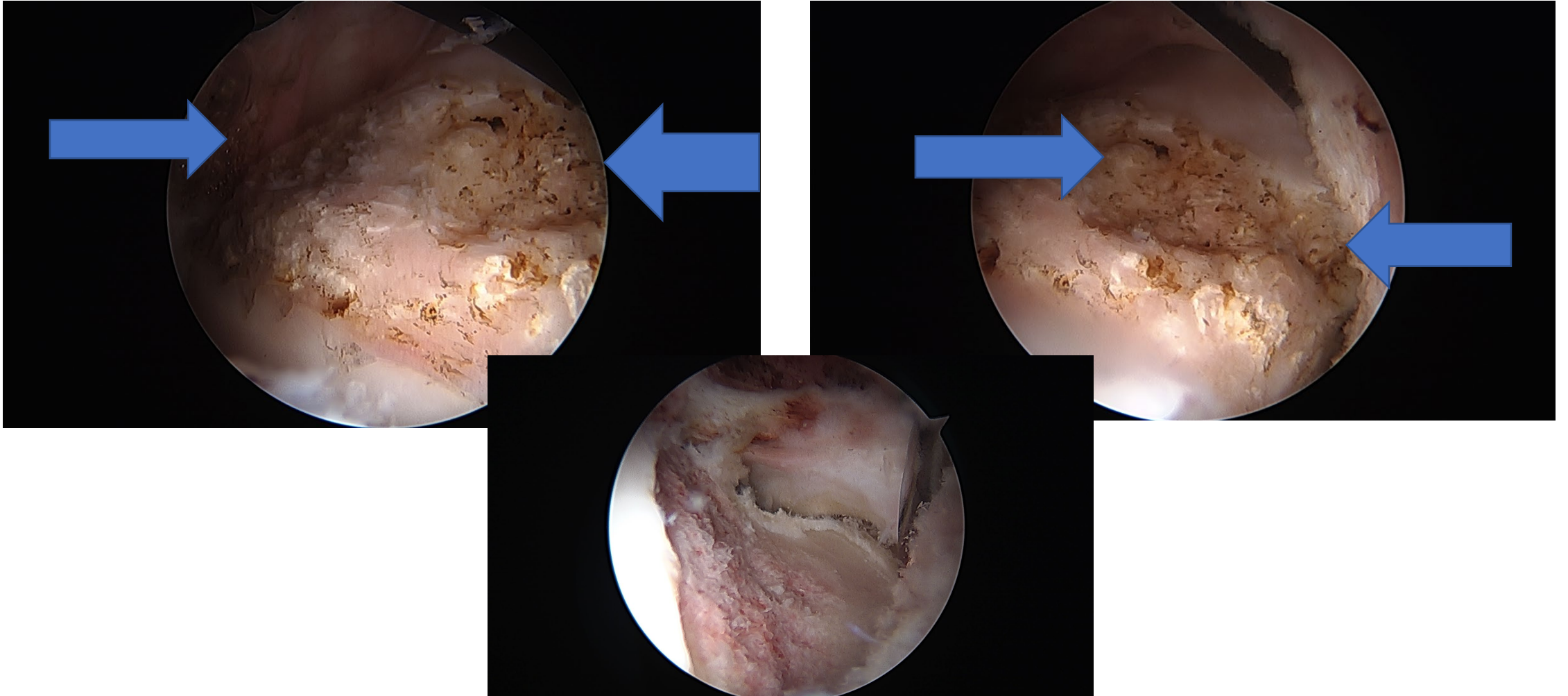


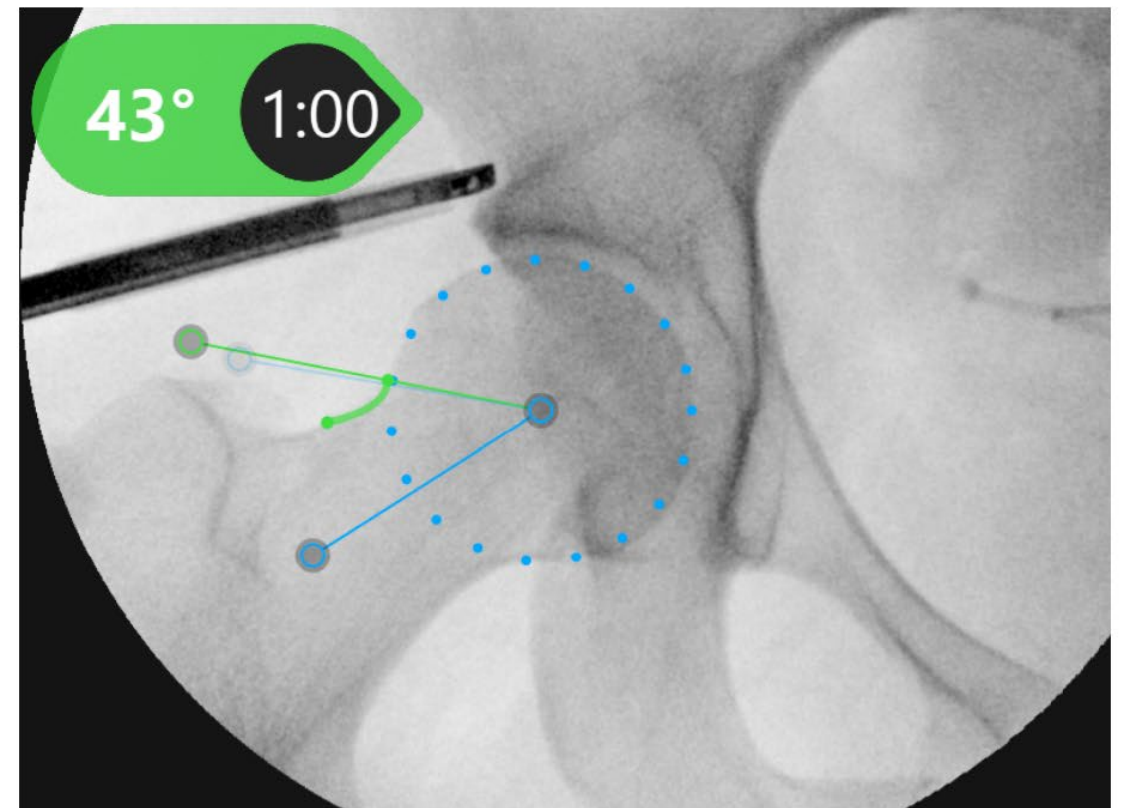
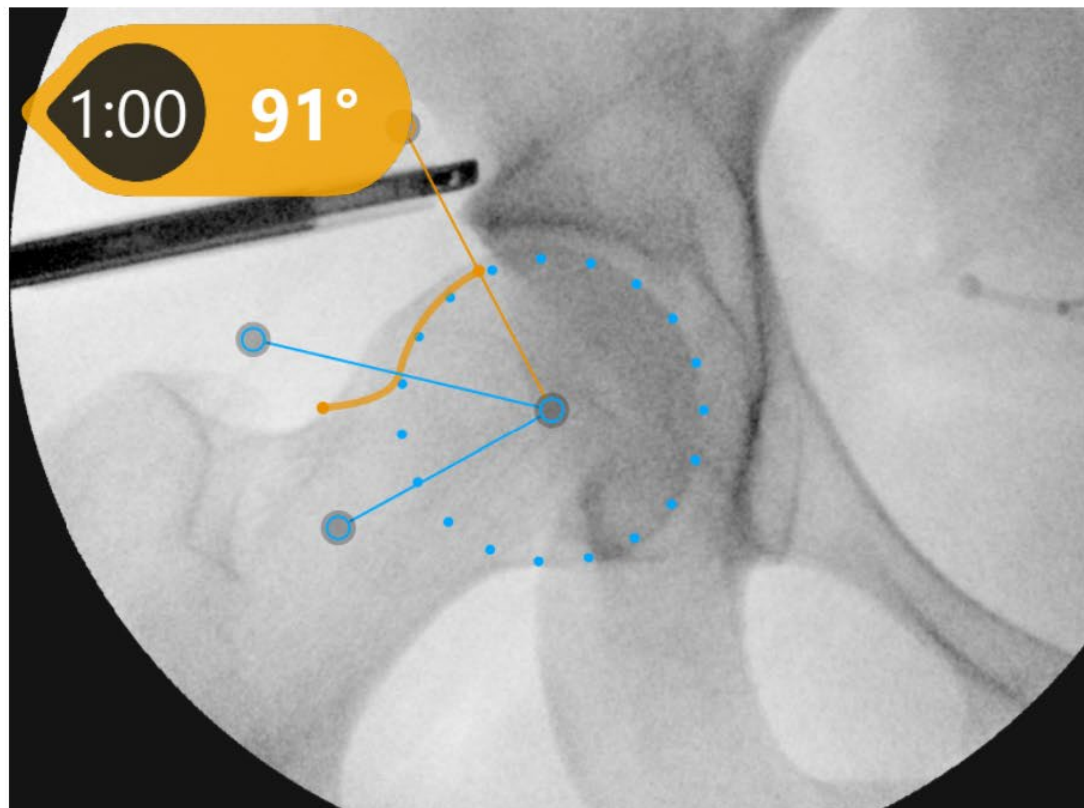
This patient had experienced so much repetitive hip impingement that they had worn a groove (blue arrows) into the femur side of the hip joint. Ouch! This was successfully smoothed away with a femoroplasty (bottom image)



Hip arthroscopy example

Before: cam deformity on the femur causing painful hip impingement. The femoral head should be spherical. The cam 'bump' (the bone outside of the circle) pinches against hip labrum and acetabulum (socket) which can cause pain, labrum tears, and cartilage damage!

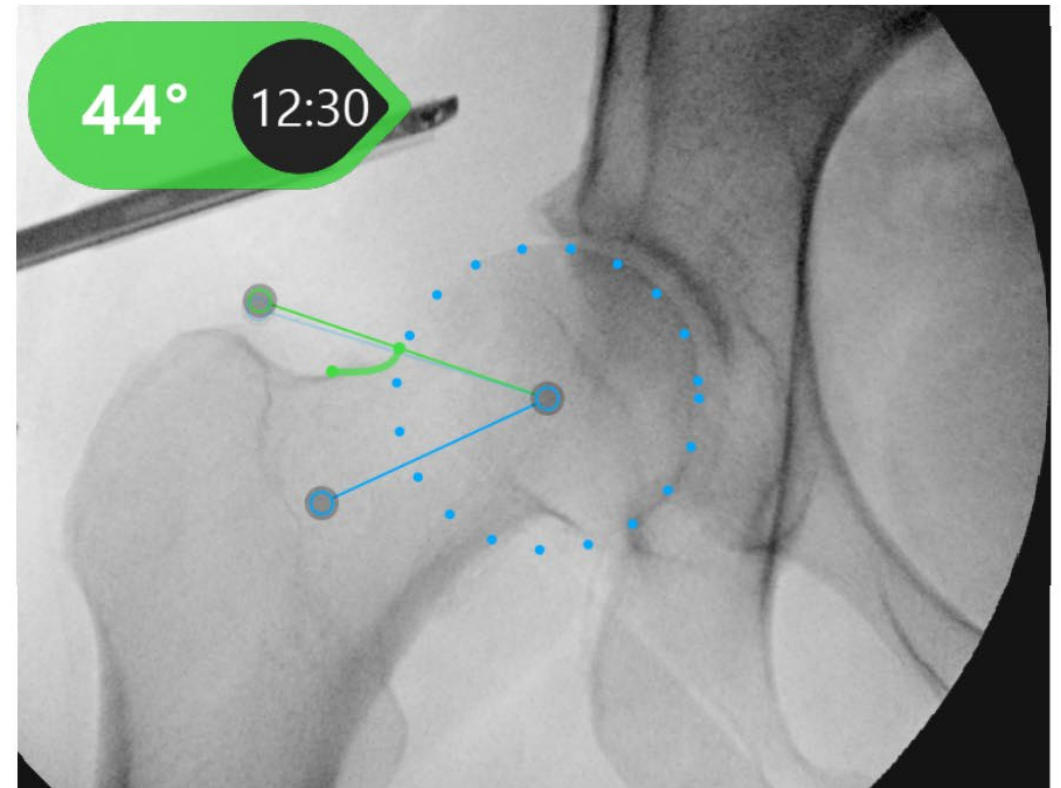
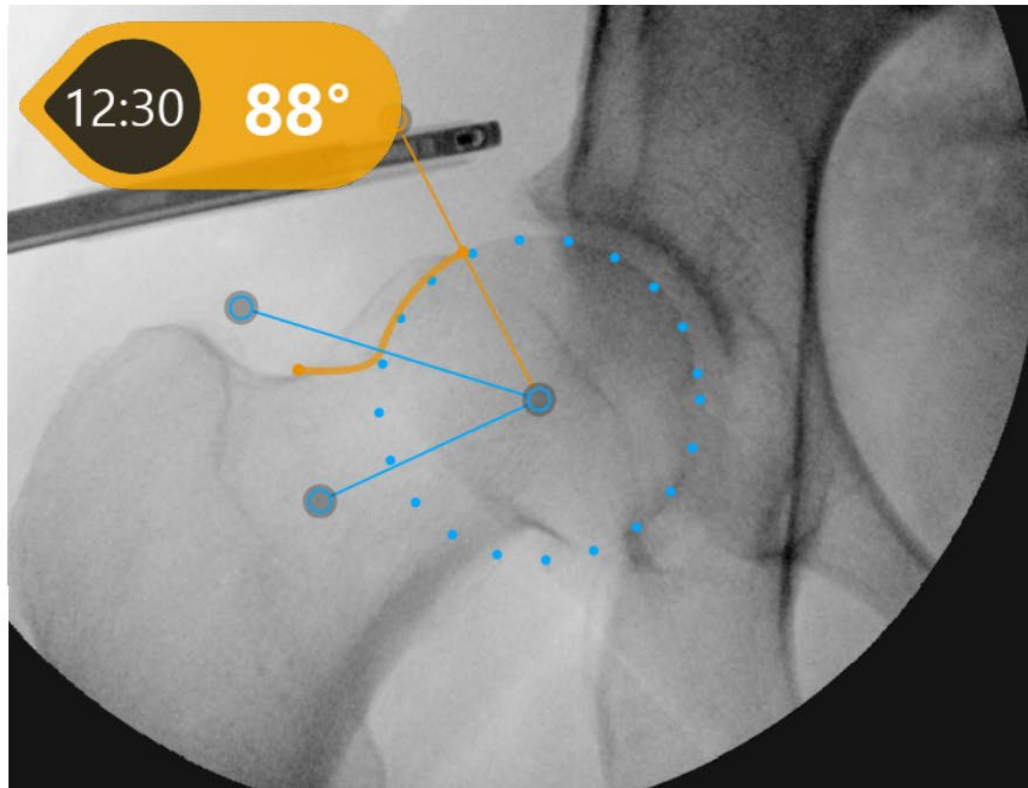
After: arthroscopic reshaping of the femur. There is now a smooth spherical shape. This eliminates hip impingement and minimizes the risk of re-injury to the hip labrum.



Hip arthroscopy example

Before: cam deformity on the femur causing painful hip impingement. The femoral head should be spherical. The cam 'bump' (the bone outside of the circle) pinches against hip labrum and acetabulum (socket) which can cause pain, labrum tears, and cartilage damage!

After: arthroscopic reshaping of the femur. There is now a smooth spherical shape. This eliminates hip impingement and minimizes the risk of hip re-injury.

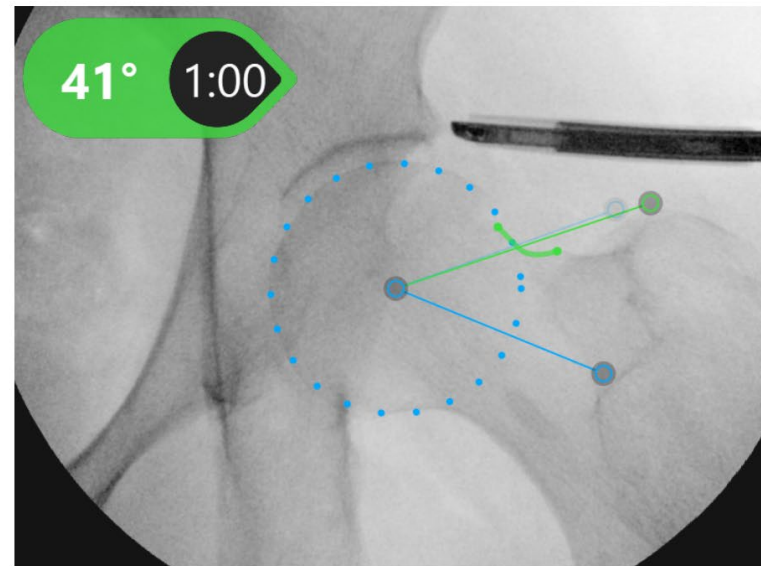
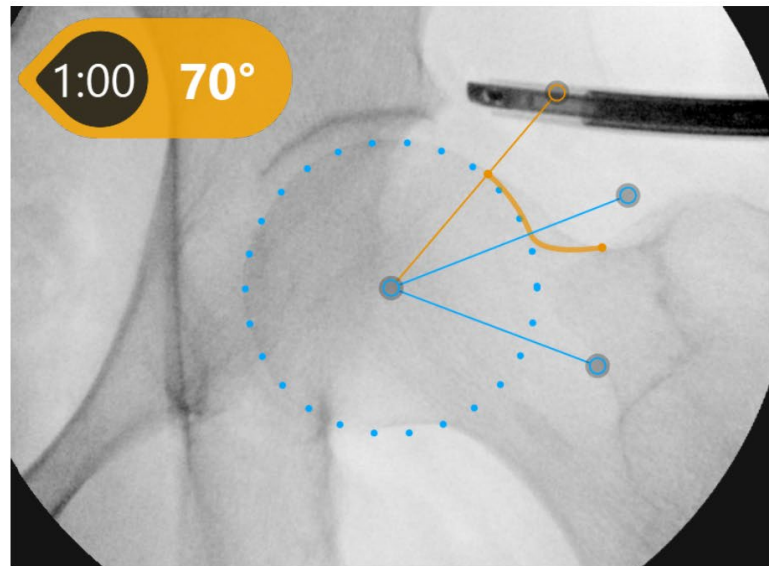


Revision hip arthroscopy example

The most common cause of failed hip arthroscopy is inadequate removal of bone that causing hip impingement. This is an example of a revision hip arthroscopy I performed to remove a cam bump that was still present after a hip arthroscopy done elsewhere. The patient recovered well and had relief of their hip pain.

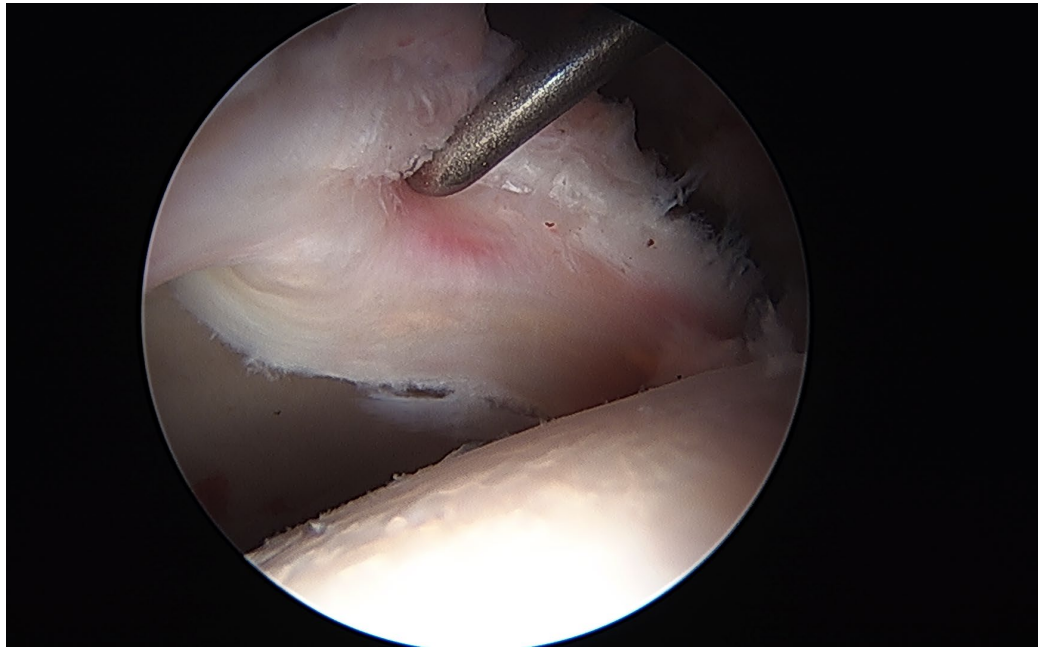
Before: cam deformity on the femur causing painful hip impingement. The femoral head should be spherical. The cam 'bump' (the bone outside of the circle) pinches against hip labrum and acetabulum (socket) which can cause pain, labrum tears, and cartilage damage!

After: arthroscopic reshaping of the femur. There is now a smooth spherical shape. This eliminates hip impingement and minimizes the risk of hip re-injury.

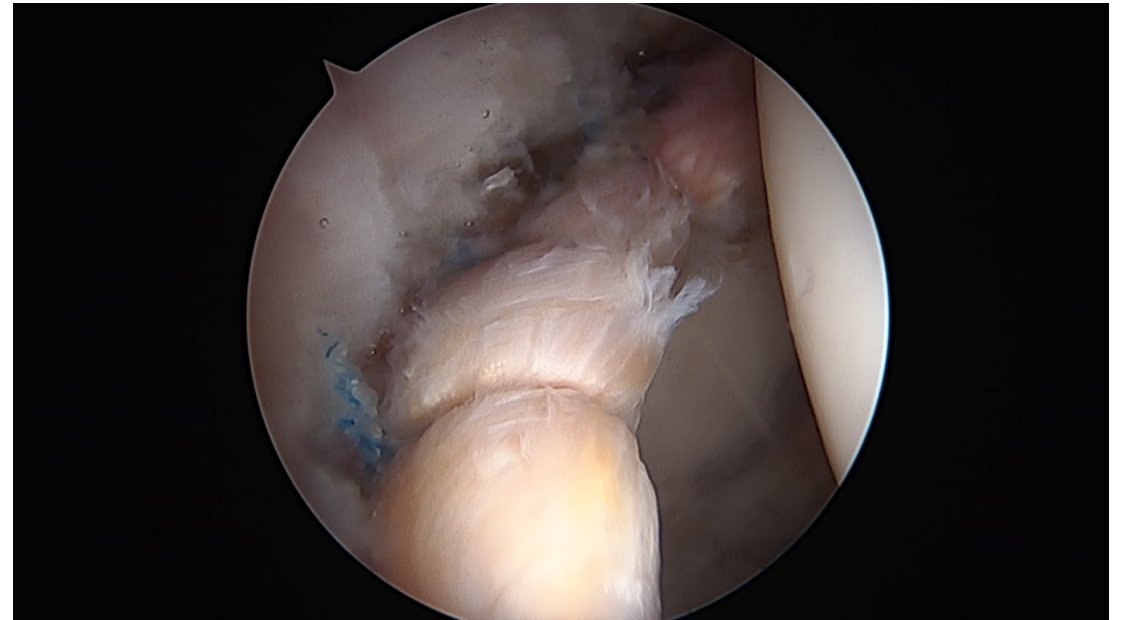


Case example: arthroscopic labrum tear

Before: acetabular labrum tear. This patient also had hip dysplasia (shallow hip socket) which causes development of a large, easily torn labrum.

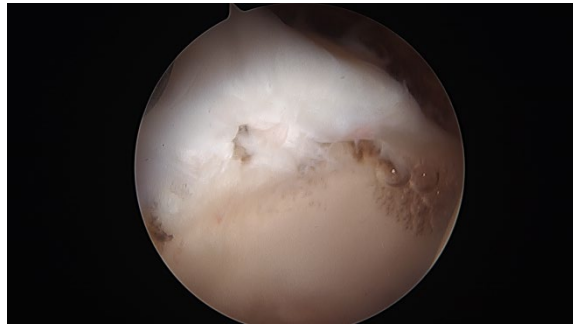


After: successful arthroscopic labrum repair. The patient also underwent a periacetabular osteotomy (PAO) with my practice partner Dr. Todd McKinley to treat the hip dysplasia. The patient recovered well and is back to her preferred physical activities.

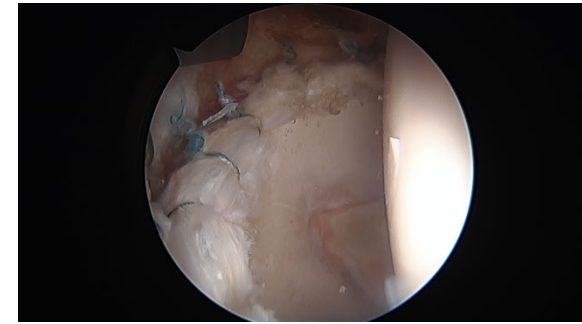


Revision hip arthroscopy with labrum re-repair. The patient's cam bump on the femur (ball) side of the hip joint had not been removed during the first hip arthroscopy performed elsewhere. This this led to a recurrent labrum tear.

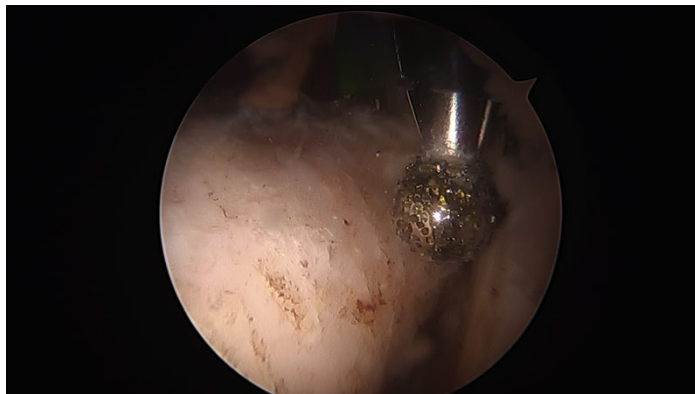Re-torn labrum (white structure at top of image)



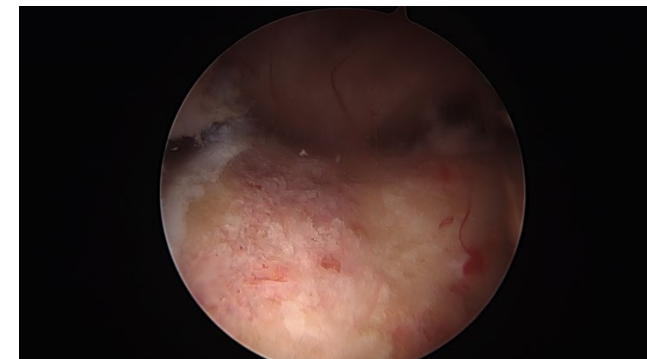Re-repaired labrum with sutures



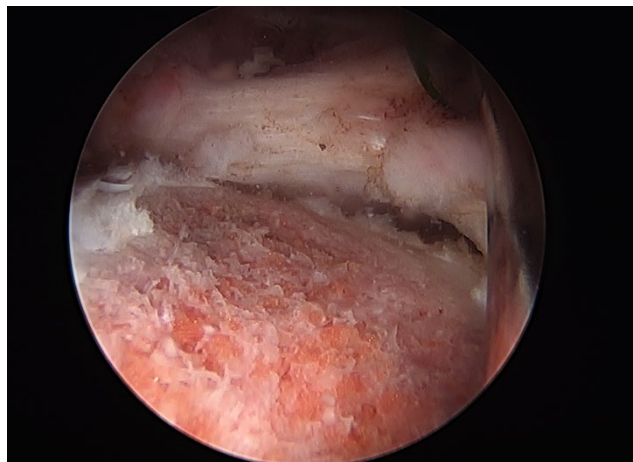
Cam bump on the femur. I reshape the femur with A special arthroscopic burr (metal object in imag)



Femur after cam bump removal. The good femoroplasty (femur reshaping) should have a gentle slope like this.

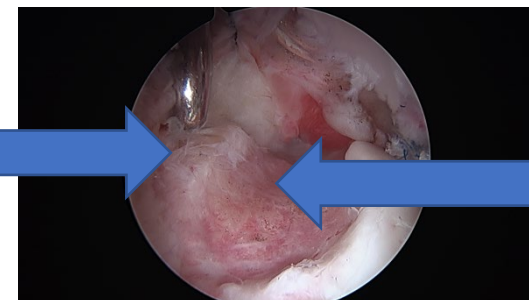


Femur (ball) side of the hip joint after arthroscopic reshaping by me. A well-done femoroplasty should have smooth, gentle slope like this to mimic the normal spherical shape of a femur that is not prone to hip impingement.

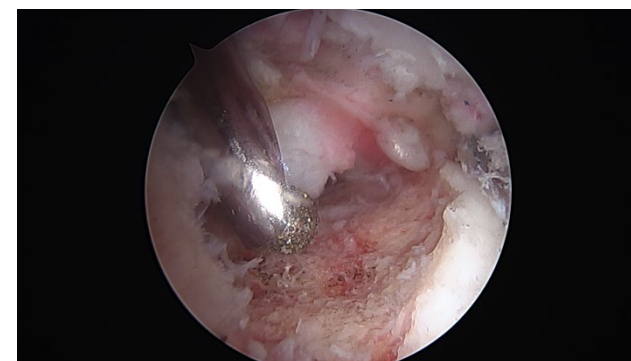

Hip arthroscopy is a difficult surgery and it is easy for surgeons without enough experience with this procedure to make technical errors! This is an example of a poorly performed femur reshaping (femoroplasty) from a hip arthroscopy done elsewhere. Too much bone was removed right next to the cartilage (note what looks like a 'cliff' on the right side), and not enough bone was removed away from the cartilage (note the bone that the metal instrument is touching on the left side). I performed revision hip arthroscopy and reshaped the femur surface to give it a gentler slope that is more like the natural shape of a hip that is not prone to hip impingement

Not enough
bone removed

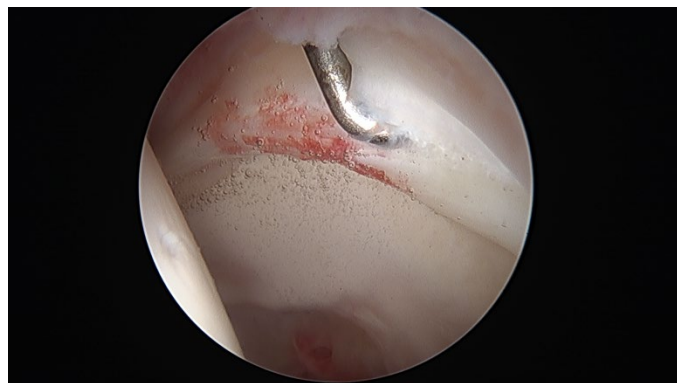

Too much bone
removed

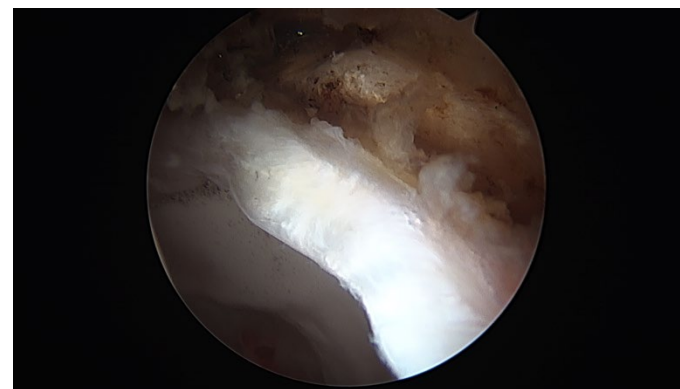

Patients can also have hip impingement and labrum tears from too much bone along the rim of the acetabulum (hip socket). This is called 'pincer' impingement. In this example there is a torn, irritated labrum and too much bone long the rim. I first moved the labrum out of the way to avoid damaging it. Then I removed the excess bone along the rim of the socket (acetabulum). This is called an acetabuloplasty. Finally, I repaired the labrum tear with sutures.

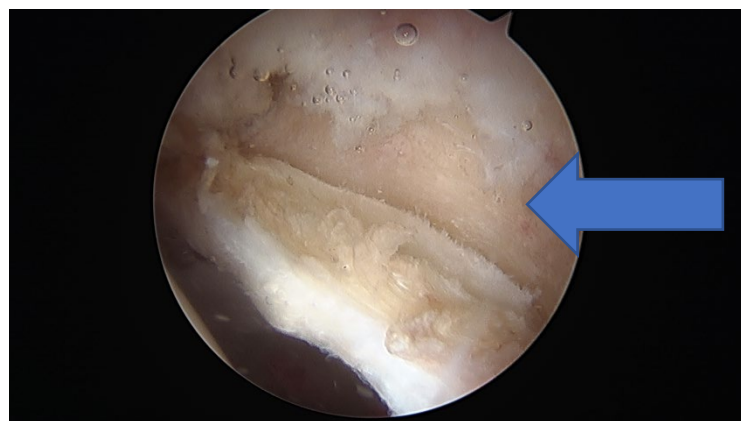
Labrum tear



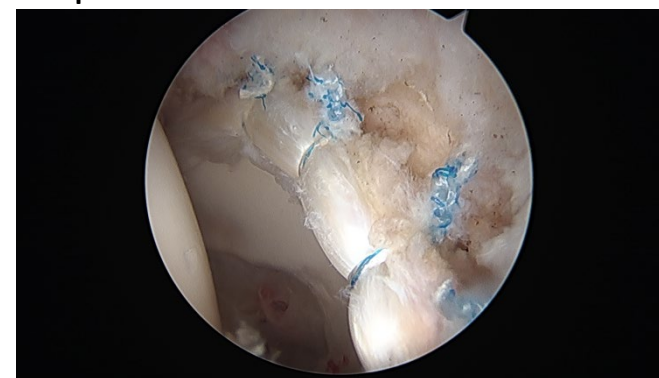I peeled the torn labrum off of the rim of the socket to avoid damaging it further when removing the excess bone from the rim of the socket.



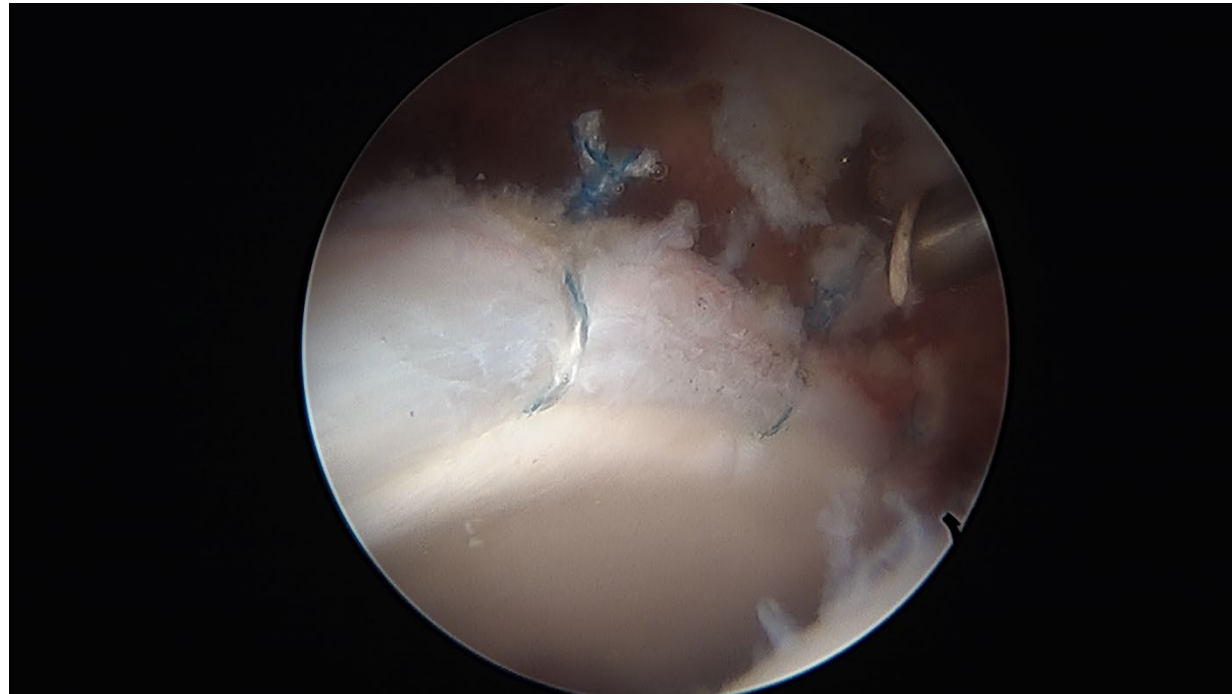
I removed the excess bone from the rim of the hip socket (acetabulum) . Now there is a smooth surface at the rim (blue arrow)



I repaired the labrum back to the rim of the acetabulum

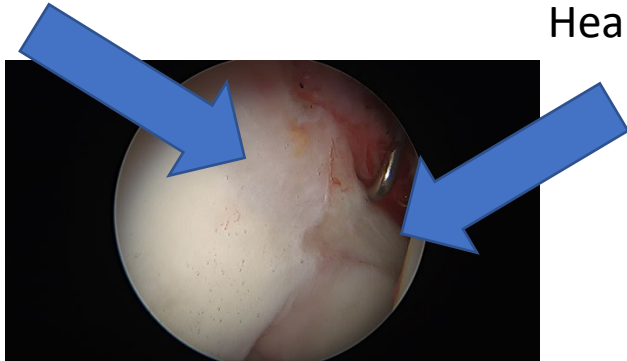


Example of an arthroscopic labrum repair performed by me



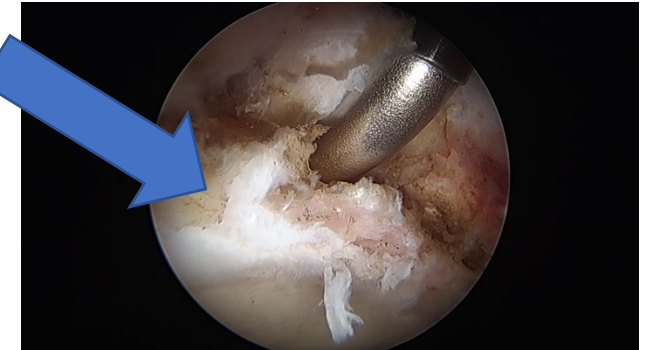
In some rare cases, chronic labrum inflammation and injury can cause the tissue to turn into bone. Part of this patient's labrum had turned into bone. This can't be repaired. I had to remove the abnormal labrum tissue and preform a labrum reconstruction. This involves removing the irreparable labrum and replacing it with tendon tissue. When performed for the right reasons, recent clinical studies have shown that labrum reconstruction patients can do as well as patients that were able to have a regular labrum repair!

Labrum turned into bone

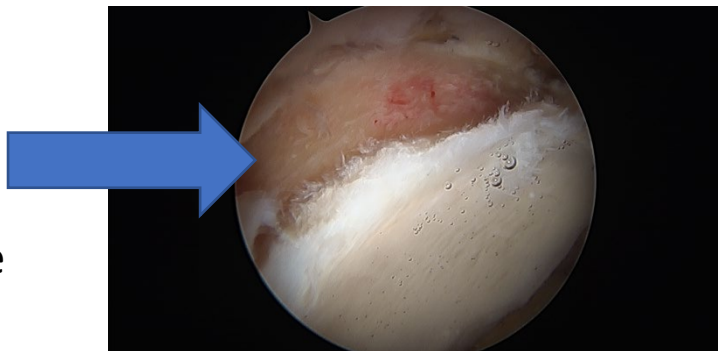


Healthy labrum

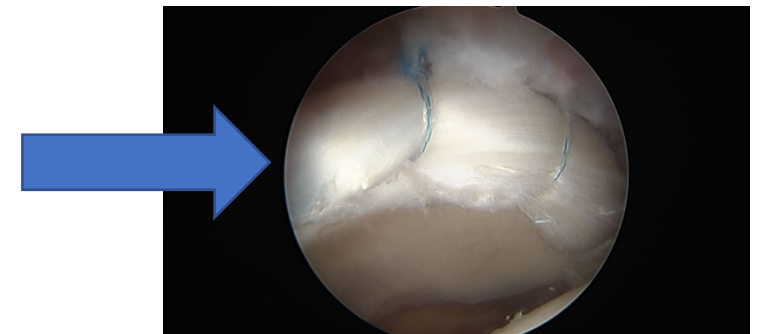
Labrum turned into bone



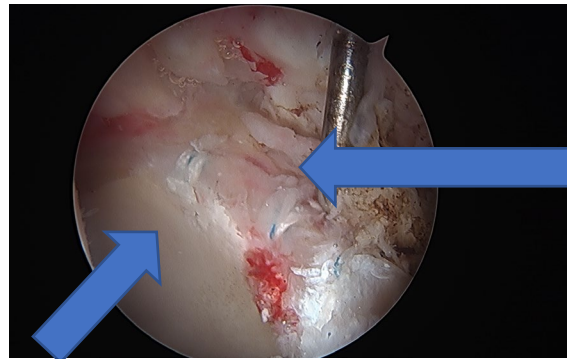
Removal of the part of the labrum that had turned into bone



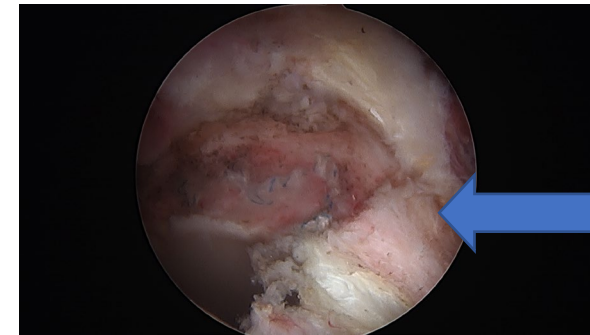
Reconstructed labrum with tendon tissue



Hip arthroscopy is a difficult surgery. It is easy for surgeons without enough experience with this procedure to make technical errors! This is an example of a poorly performed hip socket reshaping (acetabuloplasty) from a hip arthroscopy done elsewhere. The acetabuloplasty had not been finished all the way around the rim, resulting in a shelf of bone and continued impingement (pincer impingement). I performed revision hip arthroscopy and reshaped the rim of the acetabulum to give it a smooth contour and remove any remaining cause of hip impingement. The labrum tissue was badly damaged from the pincer impingement and required a labrum reconstruction. This involves replacing the irreparably damaged labrum tissue with tendon tissue. When performed for the right reasons, recent clinical studies have shown that labrum reconstruction patients can do as well as patients that were able to have a regular labrum repair!

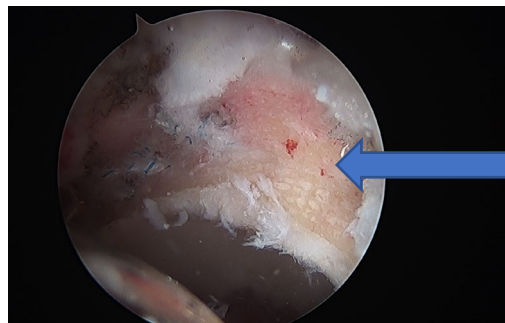

Severely damaged labrum with sutures from previous labrum repair done elsewhere

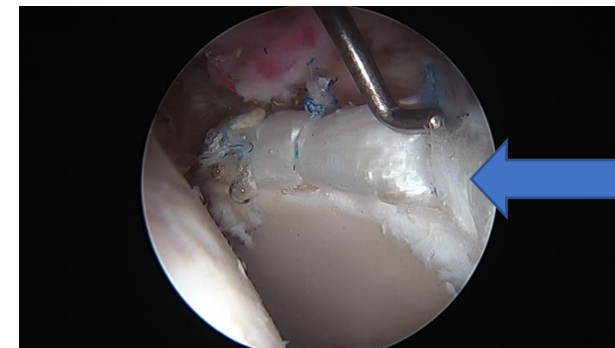


The rim of the acetabulum had not been reshaped properly and there was shelf of bone where the previous acetabuloplasty had stopped

Healthy joint surface (cartilage)



I revised the acetabuloplasty to make a smooth rim and remove any remaining cause of impingement



I reconstructed the labrum with tendon tissue to replace the severely damaged labrum